



**PATIENT**

Bubba Franco

**SPECIES**

Canine

**BREED**

Dogue DE Bordeaux

**SEX**

Male Neutered

**AGE**

6 years

**WEIGHT**

103lbs

**INTERPRETED BY**

Maggie Machen Lamy,  
DVM, DACVIM  
(Cardiology)

**IMAGING PERFORMED BY**

Kim Liedberg

**HOSPITAL NAME**

SVS Imaging WI

**REFERRING VET**

Dr. Beyer

**INVOICE**

24002

**DATE**

5/3/22

**PRESENTING CLINICAL SIGNS**

History: History of skin issues and weight gain. Bradycardia noted at exam, 45bpm on most days.

**RADIOGRAPHIC FINDINGS** \*NOTE: Images submitted for supplemental cardiac information only.

Mild cardiomegaly. No obvious evidence of CHF.

**ELECTROCARDIOGRAPHIC FINDINGS** \*Note: Single lead ECGs are evaluated as a rhythm strip.

Morphology/MEA cannot be definitively commented on.

A single lead ECG is available; 25mm/s, 10mm/mV. The average heart rate is 45bpm with a largely regular rhythm. P waves cannot be definitively identified throughout. The QRS is prolonged consistent with a ventricular origin.

ECG diagnosis: Suspect complete (3<sup>rd</sup> degree) AV block.

**ECHOCARDIOGRAM FINDINGS**

2D, m-mode, color flow and doppler imaging is available. Mild diffuse thickening of mitral valve leaflets with no prolapse into the left atrial lumen. Mild central mitral regurgitation with mild to moderate left atrial dilation. Borderline LV diameter with adequate myocardial function. The tricuspid valve appears normal with trace tricuspid regurgitation. Mild right heart enlargement. The pulmonic and aortic valves are normal in morphology and mobility. Normal pulmonic and aortic outflow velocities with laminar flow. No obvious aortic or pulmonic insufficiency. No pericardial or pleural effusion noted. No obvious cardiac masses.

**CARDIAC CHART**

CANINE CARDIAC PARAMETERS	MR VMAX (m/s)	TR VMAX (m/s)	LA/AO (Boon method)	LA/AO (Heart Base; Swe)	FS (%)	EF (%)	EPSS (cm)
NORMAL PARAMETER	4.5-5.5	<2.7	1.3	<1.6	28-40	40-100	<0.6
PATIENT	4.8	NM	NM	1.6	53	84	NM
CANINE CARDIAC PARAMETERS	HR (BPM)	AV VMAX (m/s)	PV MAX (m/s)	BODY WEIGHT (kg)	LA 2D short axis Base view (cm)	LVIDd Avg; 2D and m-mode short axis (cm)	LVIDs Avg; 2D and m-mode short axis (cm)
NORMAL PARAMETER	50-100	0.7-1.7	0.7-1.6	BELOW	BELOW	BELOW	BELOW
PATIENT	50	1.2	1.8	46.7	3.6	5.1	2.4
*Normal chamber parameters expressed as a mean value (SD)				3	1.27 (5.3)	2.46 (2.46)	1.36 (5.5)
<b>BODY WEIGHT DEPENDENT PARAMETERS</b>				5	1.40 (4.5)	2.74 (5.2)	1.60 (4.7)
*Note: All measurements based upon multi-modal images and methods. An average value is reported.				10	1.50 (3.8)	3.27 (3.5)	2.06 (3.1)
				15	1.83 (2.0)	3.71 (2.4)	2.43 (2.1)
				20	2.02 (1.9)	4.14 (2.2)	2.80 (2.0)
				25	2.18 (2.4)	4.48 (2.9)	3.10 (2.5)
				30	2.33 (3.3)	4.83 (3.9)	3.39 (3.4)
				35	2.48 (4.3)	5.17 (5.0)	3.69 (4.5)
				40	2.62 (5.2)	5.48 (6.1)	3.96 (5.4)
				50	2.88 (7.1)	6.07 (8.3)	4.46 (7.4)

Adapted from June Boon, Veterinary Echocardiography, 1998  
Rishniw M and Hollis NE, J Vet Intern Med 2000; 14:429-435  
Hansson et al, Vet Rad and Ultrasound 2002  
Bonagura et al. Echocardiography: principles of interpretation, Vet Clin North Am 15:1177, 1995

**PATIENT**

Bubba Franco

**SPECIES**

Canine

**BREED**

Dogue DE Bordeaux

**SEX**

Male Neutered

**AGE**

6 years

**WEIGHT**

103lbs

**INTERPRETED BY**Maggie Machen Lamy,  
DVM, DACVIM  
(Cardiology)**IMAGING PERFORMED BY**

Kim Liedberg

**HOSPITAL NAME**

SVS Imaging WI

**REFERRING VET**

Dr. Beyer

**INVOICE**

24002

**DATE**

5/3/22

**INTERPRETATION OF THE FINDINGS & FURTHER RECOMMENDATIONS**

The rhythm diagnosis is suspected to be 3<sup>rd</sup> degree AV block with a ventricular escape rate of 40bpm. This is suspected as the single-lead tracing is insensitive for P waves; however, atrial contraction can be seen independent of ventricular contraction throughout the echo. Significant bradycardia and AV block is usually an acutely progressive disorder, with most dogs requiring transvenous pacemaker implantation to relieve clinical signs such as collapse or lethargy. The overall cardiac dimensions are mildly enlarged with mild MR and TR, these are likely due to the arrhythmia and are hemodynamically insignificant. Follow up is advised in the future. No additional issues are identified at this time.

AV block is typically idiopathic in origin, with progressive deterioration of the electrical system resulting in persistent bradycardia, significant lethargy and collapse. An atropine challenge can be performed to ensure diagnosis with little to no response expected. These cases typically are unable to be managed medically; however, the atropine challenge will be telling. Baseline full lab work should also be performed, to rule out any electrolyte abnormalities that may be contributing.

Barring any treatable systemic issues, the recommended treatment in this case is referral for discussion of pacemaker implantation independent of clinical signs. If declined, heart rate stimulation can be attempted as discussed; however, this is of little benefit. Going forward, there is potential that the arrhythmia may remain subclinical for some time. If not corrected however, this patient will succumb to either continued cardiac dilation over time resulting in CHF (which will be difficult to manage in the absence of a normal heart rate), or to worsening bradycardia/syncope/sudden death. The goal would be to stabilize the situation through heart rate management and use medical support to hopefully support the structural disease.

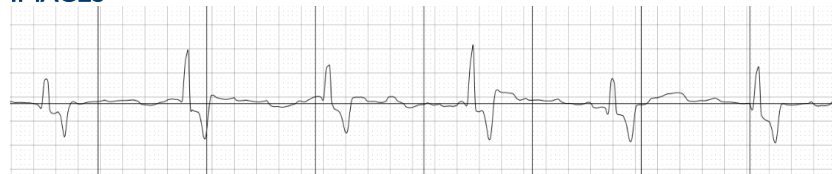
In the interim, recommend Pimobendan given for mild cardiac enlargement. Going forward, unfortunately, the patient will always be at risk for recurrent CHF, syncope and/or sudden death in the future. If patient develops syncope or QOL suffers, euthanasia or pacemaker implantation will become the only options, and this should be expressed to the owner.

**PLAN**

Consider immediate referral to a tertiary facility for further evaluation of the bradyarrhythmia and discussion of surgical intervention. Systemic work up and atropine challenge should be considered as discussed: administer 0.04mg/kg atropine IV or IM and assess response.

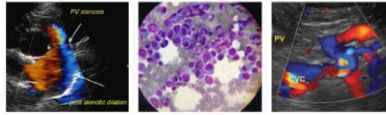
If referral is declined/not possible, institute Pimobendan 0.3mg/kg PO q12h.

If patient continues to do well at home (i.e., no collapse or lethargy), reassess echo/ECG in 3-4 months.

**IMAGES**

**IMAGING PERFORMED BY**

svsmobileimaging.com 309-737-3070



**Clinical Sonography & Telecytology**

EDUCATIONAL TELECONSULTATION SERVICES™

1-800-838-4268 info@sonopath.com SonoPath.com

**PATIENT**

Bubba Franco

**SPECIES**

Canine

**BREED**

Dogue DE Bordeaux

**SEX**

Male Neutered

**AGE**

6 years

**WEIGHT**

103lbs

**INTERPRETED BY**

Maggie Machen Lamy,  
DVM, DACVIM  
(Cardiology)

**IMAGING PERFORMED BY**

Kim Liedberg

**HOSPITAL NAME**

SVS Imaging WI

**REFERRING VET**

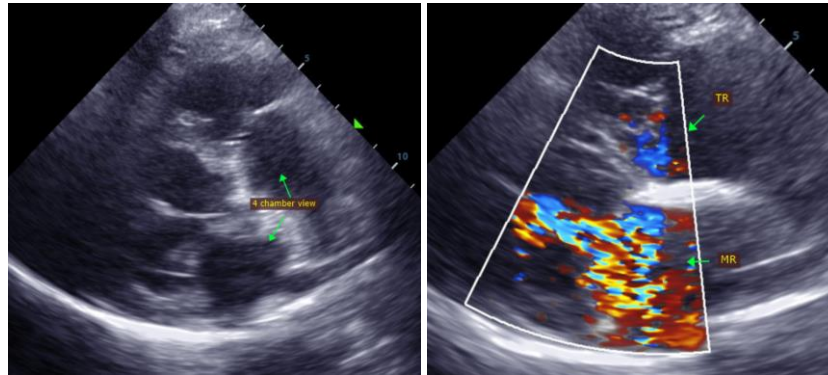
Dr. Beyer

**INVOICE**

24002

**DATE**

5/3/22



The information and recommendations provided are based on the images presented by the referring veterinarian. No evaluation can be communicated regarding pathology that was not visible in the image/video clips provided.

Thank you for this referral. If the clinical or image interpretation does not parallel your findings or if I can be of any further assistance, please contact me.

**Maggie Machen Lamy, DVM**  
Diplomate of the American College of Veterinary Internal Medicine (Cardiology)  
info@sonopath.com